



Comparative Assessment of Topical Platelet-Rich Plasma and Phenytoin for Diabetic Foot Ulcer Healing in a Rat Model

Khadiga T. Al-Thubhani¹, Doa'a A. Ibrahim^{2*}, Mahmood Al-Hammadi³

¹Department of Pharmacology, Faculty of Pharmacy, University of Science and Technology (USTY), Sana'a, Yemen

²Department of Clinical Pharmacy and Pharmacy Practice, Faculty of Pharmacy, University of Science and Technology (USTY), Sana'a, Yemen

³Department of Histopathology, Faculty of Pharmacy, University of Science and Technology (USTY), Sana'a, Yemen

* Corresponding author: Email: dr_d_anwar@hotmail.com

ABSTRACT

Background: Diabetic foot ulcer (DFU) is a major complication of diabetes, associated with increasing rates of lower-limb amputation, morbidity, and mortality. Treating DFU remains a growing medical challenge, with many current approaches failing to achieve optimal outcomes. One approved clinical approach involves regenerative therapies, such as platelet-rich plasma (PRP). Another approach is drug repurposing, including the topical use of phenytoin. This study aimed to compare the wound-healing efficacy of 1% phenytoin cream with that of PRP gel in a rat model of DFU.

Methods: This experimental study was conducted over 84 days using 20 adult male albino rats. Diabetes was induced by feeding the rats a high-fat diet for 28 days, followed by a single intraperitoneal injection of streptozotocin (STZ) at 40 mg/kg. After diabetes confirmation, diabetic neuropathy was assessed on day 42, and a wound was induced on the right hind paw of each rat on day 43 using a 6-mm biopsy punch. Wounds were treated to prevent infection for 14 days. On day 60, rats were randomly divided into two groups: diabetic wounds treated once daily with 1% phenytoin cream (DW Phen, $n = 10$) and diabetic wounds treated twice weekly with freshly prepared PRP gel (DW PRP, $n = 10$), from day 60 to day 84. Wounds were photographed on days 60, 64, 67, 70, 74, 77, 82, and 84, and wound area and contraction were recorded. On days 70, 77, and 84, two rats randomly selected from each group were sacrificed, and wound sections were obtained for histopathological assessment and immunohistochemistry (IHC) studies.

Results: PRP gel and phenytoin cream showed comparable efficacy in terms of wound contraction, histopathological findings, and IHC results. Although the PRP gel showed greater wound contraction, the differences between the DW PRP and DW Phen groups were not statistically significant. Histologically, early wound sections in the DW Phen showed edema, extravasated red blood cells, and less collagen reconstruction, whereas the DW PRP group showed more advanced granulation tissue, neovascularization, and collagen deposition. In the middle and final stages, both treatments promoted tissue repair, re-epithelialization, fibroblast proliferation, collagen organization, and hair follicle formation, with PRP showing more advanced tissue reconstruction and rete ridge restoration. IHC staining confirmed effective vascularization in both groups.

Conclusion: PRP achieves complete wound closure by day 84, whereas phenytoin shows near-complete closure, with no statistically significant difference. Wound healing is supported by enhanced tissue regeneration, re-epithelialization, and angiogenesis. PRP shows more advanced histological improvement than phenytoin. Future studies should develop standardized protocols for PRP application, with consideration of dosage form, route of administration, stability, and the molecular mechanisms underlying wound healing.

Keywords: Diabetic foot ulcer ▪ Platelet-rich plasma ▪ Phenytoin cream ▪ Rat model



1. Introduction

Diabetes mellitus (DM) is a major global health disorder with a rapidly increasing prevalence. In 2024, the estimated global diabetic population was 588.7 million people and is predicted to increase to 852.5 million people by 2050, representing a 45% increase.⁽¹⁾ DM causes several serious macrovascular and microvascular complications that influence quality of life, including retinopathy, neuropathy, diabetic foot ulcer (DFU), and nephropathy. DFU is defined as deep chronic lesions in the skin with loss of epithelium. These lesions may involve the muscle, joint, and/or bone structures and can be associated with peripheral vascular neuropathy of the lower limbs.⁽²⁾

DFU is projected to affect at least 13% of the global diabetic population in both developed and developing countries by 2045.⁽³⁾ It is becoming an increasing economic burden, especially in cases complicated by diabetic foot infection and ulcer recurrence.^(4,5)

Several therapeutic approaches for DFU management have been widely approved.^(6,7) However, limited information is available regarding comparisons between regenerative therapies and approved standard DFU treatments, particularly when histopathological and immunohistochemical examinations are used as outcome measures. Therefore, this study aimed to compare platelet-rich plasma (PRP) gel and phenytoin cream for DFU healing in a rat model.

2. Methods

2.1. Study design and experimental animals

This experimental study was conducted at the Master Research Laboratory of the University of Science and Technology, Sana'a, Yemen, over a period of 84 days. Twenty adult male albino rats weighing 180 ± 20 g and aged 10–12 weeks were obtained from the animal house of the Biology Department, Faculty of Science, Sana'a University,

Yemen. Rats were acclimatized to laboratory conditions for one week before the beginning of the experiment. They were kept in metal cages with free access to clean drinking water and were fed a standard pellet diet. Rats were weighed, numbered, marked, and fed a high-fat diet (HFD) throughout the study.⁽⁸⁾

2.2. Induction and confirmation of DM in rats

DM was induced by a combination of 28 days of HFD, followed by a single intraperitoneal dose of streptozotocin (STZ) at 40 mg/kg.⁽⁹⁾ STZ was administered after overnight fasting, with only water accessible. The next day, rats were injected with a freshly prepared single dose at 40 mg/kg after it had been dissolved in 0.1 M citrate buffer (pH 4.5).⁽¹⁰⁾ STZ injection was followed by continued HFD feeding during the recovery period.⁽¹¹⁾

After 72 hours of STZ injection, diabetes was confirmed by measuring fasting blood sugar (FBS) using Accu-Chek Instant glucometer (Roche Diabetes Care GmbH, Mannheim, Germany). Blood was drawn from the tip of each rat's tail. Rats with FBS levels exceeding 250 mg/dL were included in the experiment.^(10,12) On day 42, neuropathy was evaluated using thermal and mechanical methods.^(13,14) Body weight and FBS were monitored throughout the experiment.

2.3. Induction of foot ulcer

On the day following neuropathy, wounds were created in both groups on the right hind paw of each rat using a 6-mm diameter biopsy punch, carefully following a previously published study.⁽¹⁵⁾ All rats were treated to prevent or control bacterial infection and were kept individually in separate cages.⁽¹⁶⁾

2.4. Preparation of PRP gel and phenytoin cream

Wound treatment started on day 60 by preparing fresh PRP gel and phenytoin cream according to the experimental design. Phenytoin cream (1%) was prepared in the research laboratories of Global Pharma



Industry, Sanaa, Yemen. This cream was formulated as a water-in-oil formulation, with slight modifications based on previous studies.⁽¹⁷⁻¹⁹⁾

PRP gel was freshly prepared for each rat on the day of PRP gel application according to a previous study.⁽²⁰⁾ The preparation of PRP gel followed several steps, including blood collection, blood centrifugation to produce PRP, activation of PRP using thrombin and calcium gluconate, and final gel formation.⁽²⁰⁾

2.5. Experimental design

The experimental design included two diabetic groups after randomization: a diabetic group with a wound treated once daily with 1% phenytoin cream (DW Phen), and a diabetic group with a wound treated twice weekly with topical PRP gel (DW PRP).

2.6. Wound closure assessment

Wounds were photographed on treatment days 60, 64, 67, 70, 74, 77, 82, and 84. Wound area was measured in square millimeters from wound photographs using AutoCAD image analysis software (Autodesk Inc., San Francisco, CA, USA). The percentage of wound closure (WC) was calculated using the following formula:^(21,22)

$$WC (\%) = [(Initial\ wound\ area - Wound\ area\ on\ day\ X) / Initial\ wound\ area] \times 100$$

The initial wound area represented the wound area on day 60, and the wound area on day X represented the measured wound area on each subsequent assessment day.

2.7. Histopathological and immunohistochemical assessment

On days 70, 77, and 84, two rats randomly selected from each group were sacrificed, and the tissue surrounding the wound area was excised from each rat, fixed in 10% formalin, and processed into paraffin

blocks for further histopathological examination according to standard procedures.⁽²³⁾ Histopathological studies included both hematoxylin and eosin (H&E) and Masson's trichrome staining.⁽¹¹⁾

Immunohistochemistry (IHC) was performed to investigate CD31 expression in the experimental tissue samples based on staining intensity and localization. IHC was carried out by sectioning tissue from the paraffin blocks and performing standard procedures according to previous studies.^(15,24,25)

2.8. Data analysis

Data were analyzed using GraphPad Prism, version 8.4 (San Diego, CA, USA) and presented as mean \pm standard deviation (SD). The mean wound contraction measurements over the treatment period were compared using the independent-samples t-test, with *P*-value <0.05 considered statistically significant.

3. Results

3.1. Percentage of DFU contraction

Table 1 shows that wound contraction in the DW PRP group was comparable to that in the DW Phen group on all follow-up days, with no statistically significant differences between groups on any follow-up day (all *P*-values >0.05).

Table 1: Comparison of the mean percentage of DFU contraction between DW PRP and DW Phen groups in male adult albino rats

Day	DW Phen	DW PRP	<i>P</i> -value
	Mean \pm SD	Mean \pm SD	
Day 64	13.61 \pm 16.54	15.82 \pm 10.70	0.728
Day 67	49.24 \pm 31.38	53.83 \pm 27.04	0.731
Day 70	67.82 \pm 22.16	69.88 \pm 19.55	0.847
Day 74	78.30 \pm 19.01	80.14 \pm 15.44	0.835
Day 77	84.19 \pm 17.01	93.80 \pm 7.56	0.235
Day 82	90.01 \pm 12.77	98.15 \pm 2.25	0.155
Day 84	94.64 \pm 7.87	100.00 \pm 0.00	0.222

DFU, diabetic foot ulcer; DW Phen, diabetic wound treated with phenytoin; DW PRP, diabetic wound treated with platelet-rich plasma; SD, standard deviation.

Figure 1 shows progressive wound contraction in both the DW Phen and DW PRP groups from day 64 onward, with more advanced closure observed from day 74.



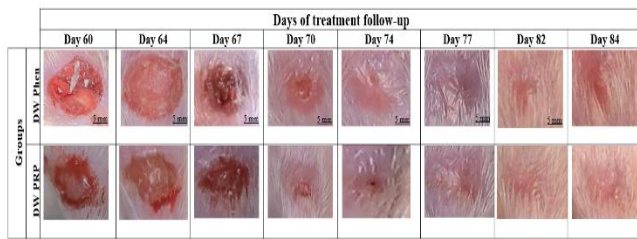

Figure 1: Digital photographs showing wound contraction progression in adult male albino rats treated with phenytoin and PRP during the follow-up period

3.2. Histopathological results

3.2.1. H&E findings in wound sections

H&E staining on days 70, 77, and 84, representing the early, middle, and final stages of wound healing, respectively, showed well-structured angiogenesis and tissue repair in both DW PRP and DW Phen groups, with more advanced improvement in the PRP group.

Figure 2 shows that, on day 70, the DW Phen group showed injured tissue with edema (E) and extravasated red blood cells (RBCs), whereas the DW PRP group showed more advanced healing, with resolution of the scab and edema, epidermal regrowth, and advanced subepidermal granulation tissue (Gr) rich in newly formed blood vessels (BV).

On day 77, the DW Phen group showed scattered fibroblasts (F), with nearly complete re-epithelialization, while the DW PRP group showed more advanced epidermal-dermal regeneration, abundant fibroblasts (F), restored rete ridges, and early adnexal regeneration (RE). By day 84, both the DW Phen and DW PRP groups showed evidence of improved healing, including intact re-epithelialization, restored adnexal structures, and immature hair follicles (HF). In addition, the DW PRP group showed abundant fibroblasts (F), focal restored rete ridges (RR), and immature hair follicles (HF).

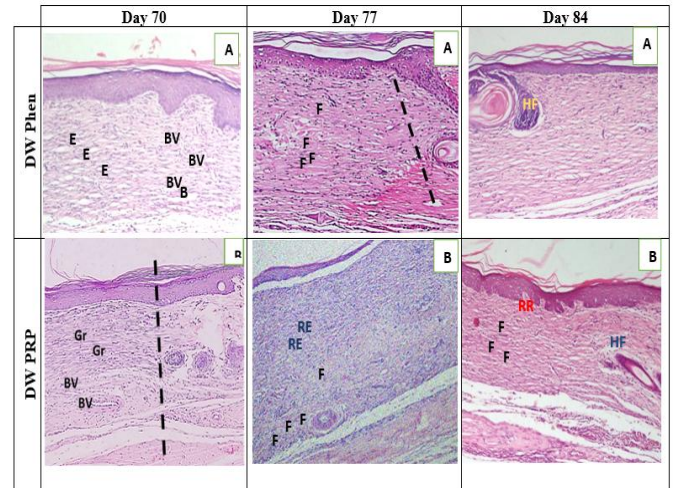


Figure 2: Photomicrographs of histopathological wound sections from DW Phen and DW PRP groups on days 70, 77, and 84. Sections were stained with H&E and examined at 100× magnification.

3.2.2. Masson's trichrome findings in wound sections

Figure 3 shows the Masson's trichrome staining findings on days 70, 77, and 84, representing healing progression. Across all three assessment periods, both phenytoin and PRP groups showed collagen deposition, with the PRP group showing more organized collagenization and immature adnexal restoration with parallel collagen fibers.

Day 70 demonstrated clear collagen deposition (COL) in both DW Phen and DW PRP groups. The DW Phen group showed less advanced and less organized mature parallel collagen fibers compared with the DW PRP group. Moreover, on day 77, the DW Phen group showed less organized collagen than the DW PRP group. Finally, day 84 showed that the DW Phen group displayed subepithelial collagen, while the DW PRP group maintained parallel horizontal collagenization.

3.3. Immunohistochemical results

Figure 4 shows CD31 expression, as assessed by IHC, throughout the study. Microvascular formation indicated angiogenesis and neovascularization in both the DW Phen and DW PRP groups. In the early stage, on day 70, the phenytoin and PRP groups showed



wound-healing angiogenesis with marked blood vessel formation and high microvessel density. In the middle stage, on day 77, wound healing proceeded with a reduction in the number of blood vessels in both the DW Phen and DW PRP groups. In the final stage, on day 84, both groups had a similar number of capillaries.

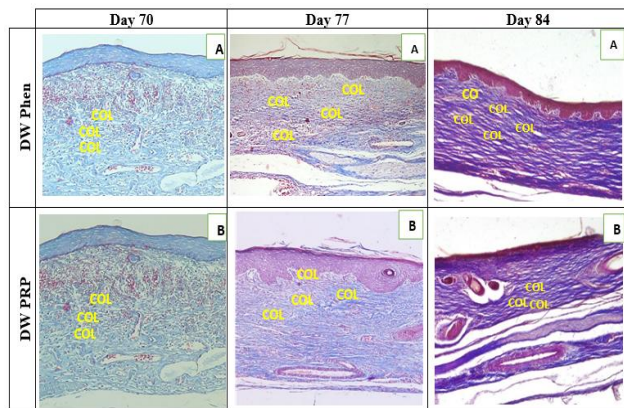


Figure 3: Photomicrographs of histopathological wound sections from DW Phen and DW PRP groups on days 70, 77, and 84. Sections were stained with Masson's trichrome and examined at 100× magnification.

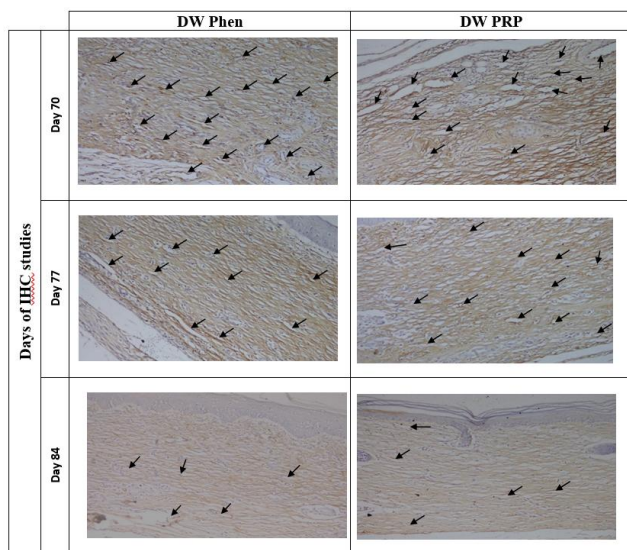


Figure 4: Photomicrographs of immunohistochemical sections of wounds from DW Phen and DW PRP groups on days 70, 77, and 84. Sections were stained for CD31 and examined at 200× magnification. Black arrows indicate CD31-positive blood vessels/vascular endothelial cells

4. Discussion

DFU represents a major clinical challenge in patients with DM because impaired wound healing is closely associated with defective angiogenic responses.^(7, 26-28) Ideal DFU management requires accurate diagnosis, early intervention, complete wound healing, infection control, and good glycemic control.⁽²⁶⁾ Globally, considerable attention has been directed toward the benefits of regenerative medicine, such as PRP, and other treatments, like phenytoin cream, for managing DFU.^(29,30) However, to our knowledge, direct preclinical comparisons between PRP gel and topical phenytoin cream in diabetic wound models remain limited. Therefore, this study assessed wound healing progression using macroscopic, histopathological and IHC findings.

The present findings regarding wound contraction after phenytoin cream application, together with the digital photographs, are consistent with previous results.^(18,29,31,32) Topical phenytoin has been reported to rapidly contract wounds, mainly through stimulation of fibroblast proliferation, myofibroblast proliferation, and tissue granulation,⁽¹⁹⁾ which were clearly seen in the histological results of this study. Furthermore, the inhibition of collagenase and formation of extracellular matrix (ECM) may contribute to the wound-healing effect of phenytoin.^(33,34) These findings align with those of a recent rabbit model of diabetic pressure ulcers, which reported that 10% phenytoin cream achieved complete wound closure by day 20, whereas placebo-treated wounds closed only after day 28, with a significant difference between groups.⁽¹⁸⁾

Similarly, a rat wound-healing study using morphological assessment, H&E staining, and Masson's trichrome staining showed that positively charged chitosan-alginate nanoparticles accelerated wound repair, achieving 56.54% wound closure by day 7. This formulation was associated with mature dermal architecture, including hair follicles and glands, the



highest collagen density of 63.7%, and better collagen organization than other treatment groups.⁽²⁹⁾ In contrast, another experimental study of 76 albino rats with incised open wounds reported no significant difference in wound contraction between phenytoin powder and normal saline. In the phenytoin group, wound area decreased from 327.9 ± 34.9 mm² on day 3 to 3.6 ± 0.9 mm² on day 28, while in the saline group it decreased from 326.8 ± 43.9 mm² to 4.3 ± 1.9 mm² over the same period.⁽³¹⁾ Despite comparable contraction rates, phenytoin was associated with a shorter epithelialization time, greater neovascularization, and higher tensile strength on histological assessment, suggesting that phenytoin may enhance qualitative aspects of wound repair even when its effect on gross wound contraction is not statistically significant.⁽³¹⁾ The wound-healing effects of phenytoin cream have been reported, particularly under ischemic conditions; however, its routine use is not recommended without further supporting evidence.⁽³⁵⁾ Another study on second-degree burn wound healing compared 3% phenytoin cream, Hypericin cream, and normal saline, and confirmed the superior long-term maturation and complete skin closure associated with phenytoin treatment.⁽³⁶⁾

The findings of this study demonstrated the strong enhancing effect of PRP on the wound-healing rate, which is consistent with prior studies.^(25,37,38) PRP is known to promote healing in different types of dermal conditions due to its unique mixture of vital growth factors, interleukins, cytokines and its ability to facilitate matrix flexibility.⁽³⁸⁻⁴⁰⁾ Several other healing mechanisms, such as ECM remodeling, modulation of inflammation, reduction of oxidative stress, and antimicrobial activity, contribute to creating a favorable internal environment that collaborate to heal wounds.⁽⁴⁰⁾

Consistent with the present findings, PRP improved wound healing, with formation of granulation as early as day 5 and well-structured fine horizontal

parallel collagen fiber formation in PRP group, resembling the remodeling stage of wound healing. PRP was found to lead to high rates of cytokine expression in wounds.⁽²⁵⁾

In line with this study, another study used injectable PRP and compared it alone, adipose-derived stem cells alone, and a combination of both PRP and adipose-derived stem cells in treating full-thickness skin defects on the back of diabetic rats. The combined PRP and adipose-derived stem cell group showed a statistically significant higher wound contraction, with the highest wound-closure speed and complete wound closure on day 10, with better tissue architecture compared with PRP alone using IHC methods. The findings were reflected by cellular migration, with keratinocytes and fibroblasts demonstrating active wound-repair responses.⁽³⁸⁾ A similar study proved that the combination of sucralfate with PRP showed good healing results when compared to PRP or sucralfate alone.⁽¹⁵⁾ The combination of cellular and acellular components provides a more sophisticated model for evaluating wound-healing treatments.^(41,42)

Overall, these findings should be interpreted with consideration of variability among studies in ulcer location, diabetic rat models, and dosage forms of phenytoin and PRP. Phenytoin supported healing through a more targeted approach, highlighting different mechanistic pathways underlying its therapeutic action, whereas PRP showed a more regenerative profile. Further quantitative studies are needed to validate the comparison between phenytoin cream and PRP for DFU wound healing in rats.

This study has several limitations. First, the small sample size and a lack of sample size calculation might limit statistical power. Second, the histopathological and IHC findings were mainly descriptive, without quantitative collagen morphometry or CD31-positive microvessel density analysis. Finally, although the hind-paw wound model reproduces selected fea-



tures of impaired diabetic wound healing, it does not fully represent the complexity of human DFU.

5. Conclusion

PRP achieves complete wound closure by day 84, whereas phenytoin shows near-complete closure, with no statistically significant difference. Wound healing is supported by enhanced tissue regeneration, re-epithelialization, and angiogenesis. PRP shows more advanced histological improvement than phenytoin. Future studies should develop standardized protocols for PRP application, considering dosage form, route of administration, stability, and the molecular mechanisms underlying wound healing.

Acknowledgments

The authors thank Reem K. Farag from the Histology Department, National Cancer Institute of Egypt, Cairo, Egypt, and Mohammed A. Aladheri from the Department Pathobiology, Ar-Rasheed Smart University, Sana'a, Yemen, for their help with the practical aspects of this work, as well as all colleagues who assisted me in the preparation and completion of this study.

Ethical approval

The study was approved by the Research Ethics Committee of the University of Science and Technology, Sana'a, Yemen (Ethical Clearance No.: 1445/004/UREC/ UST).

Conflict of interest

The authors declare no conflict of interest associated with this article.

Funding

None.

References

1. International Diabetes Federation. IDF Diabetes Atlas. 11th ed. Brussels: International Diabetes Federation; 2025. [Google Scholar](#)
2. Everett E, Mathioudakis N. Update on management of diabetic foot ulcers. *Ann N Y Acad Sci*. 2018;1411(1):153–65. [DOI](#) • [PubMed](#) • [Google Scholar](#)
3. Saeedi P, Petersohn I, Salpea P, Malanda B, Karuranga S, Unwin N, et al. Global and regional diabetes prevalence estimates for 2019 and projections for 2030 and 2045: results from the International Diabetes Federation Diabetes Atlas. *Diabetes Res Clin Pract*. 2019;157:107843. [DOI](#) • [PubMed](#) • [Google Scholar](#)
4. Armstrong DG, Tan TW, Boulton AJM, Bus SA. Diabetic foot ulcers: a review. *JAMA*. 2023;330(1):62–75. [DOI](#) • [PubMed](#) • [Google Scholar](#)
5. McDermott K, Fang M, Boulton AJM, Selvin E, Hicks CW. Etiology, epidemiology, and disparities in the burden of diabetic foot ulcers. *Diabetes Care*. 2023;46(1):209–21. [DOI](#) • [PubMed](#) • [Google Scholar](#)
6. Schaper NC, van Netten JJ, Apelqvist J, Bus SA, Fitridge R, Game F, et al. Practical guidelines on the prevention and management of diabetes-related foot disease (IWGDF 2023 update). *Diabetes Metab Res Rev*. 2024;40(3):e3657. [DOI](#) • [PubMed](#) • [Google Scholar](#)
7. Raja JM, Maturana MA, Kayali S, Khouzam A, Efeovbokhan N. Diabetic foot ulcer: a comprehensive review of pathophysiology and management modalities. *World J Clin Cases*. 2023;11(8):1684. [DOI](#) • [PubMed](#) • [Google Scholar](#)
8. Gheibi S, Bakhtiarzadeh F, Ghasemi A. A review of high fat diet-streptozotocin model for induction of type 2 diabetes in rat. *Iran J Endocrinol Metab*. 2016;18(2):135–48. [Google Scholar](#)
9. Reed MJ, Meszaros K, Entes LJ, Claypool MD, Pinkett JG, Gadbois TM, et al. A new rat model of type 2 diabetes: the fat-fed, streptozotocin-treated rat. *Metabolism*. 2000;49(11):1390–4. [DOI](#) • [PubMed](#) • [Google Scholar](#)
10. Ghasemi A, Jeddi S. Streptozotocin as a tool for induction of rat models of diabetes: a practical guide. *EXCLI J*. 2023;22:274. [DOI](#) • [PubMed](#) • [Google Scholar](#)
11. Cheng KY, Lin ZH, Cheng YP, Chiu HY, Yeh NL, Wu TK, et al. Wound healing in streptozotocin-induced diabetic rats using atmospheric-pressure argon plasma jet. *Sci Rep*. 2018;8(1):12214. [DOI](#) • [PubMed](#) • [Google Scholar](#)
12. Albanna AA, Ibrahim DAA, Shamsheer AM, Al-Shawia MA, Halboup A. The potential effect of dapagliflozin and liraglutide in attenuating cardio-renal injuries in diabetic rats. *J Exp Pharmacol*. 2025;17:467–84. [DOI](#) • [PubMed](#) • [Google Scholar](#)
13. Ostovar M, Akbari A, Anbardar MH, Iraj A, Salmanpour M, Ghoran SH, et al. Effects of *Citrullus colocynthis* L. in a rat model of diabetic neuropathy. *J Integr Med*. 2020;18(1):59–67. [DOI](#) • [PubMed](#) • [Google Scholar](#)
14. Mehta BK, Nerkar D, Banerjee S. Characterization of peripheral neuropathy in rat model of type 2 diabetes. *Indian J Pharm Educ Res*. 2017;51(1):92–101. [DOI](#) • [Google Scholar](#)
15. Yuniati R, Innelya I, Rachmawati A, Charlex HJM, Rahmatika A, Khrisna MB, et al. Application of topical sucalfate and topical platelet-rich plasma improves wound healing in diabetic ulcer rats wound model. *J Exp Pharmacol*. 2021;13:797–806. [DOI](#) • [PubMed](#) • [Google Scholar](#)
16. Jain D, Bansal MK, Dalvi R, Uppanlawar A, Somani R. Protective effect of diosmin against diabetic neuropathy in experimental rats. *J Integr Med*. 2014;12(1):35–41. [DOI](#) • [PubMed](#) • [Google Scholar](#)
17. Mulkalwar S, Behera L, Golande P, Manjare R, Patil H. Evaluation of wound healing activity of topical phenytoin in an excision wound model in rats. *Int J Basic Clin Pharmacol*. 2015;4(1):139–43. [Google Scholar](#)



18. Ali BA, Al-Nahari M. Formulation and investigation of phenytoin cream for wound healing in rabbits. *Al-Rafidain J Med Sci.* 2024;7(2):177–82. [Google Scholar](#)
19. Ye A. Phenytoin 1% topical cream. *US Pharm.* 2025;50(11):59–60. [Google Scholar](#)
20. Cetinkaya R, Yilmaz S, Ünlü A, Petrone P, Marini C, Karabulut E, et al. The efficacy of platelet-rich plasma gel in MRSA-related surgical wound infection treatment: an experimental study in an animal model. *Eur J Trauma Emerg Surg.* 2018;44:859–67. [DOI](#) • [PubMed](#) • [Google Scholar](#)
21. Dolibog PT, Dolibog P, Chmielewska D. Determining the measurement accuracy in assessing the progress of wound healing. *Adv Dermatol Allergol.* 2023;40(4):554–60. [DOI](#) • [PubMed](#) • [Google Scholar](#)
22. Eid HM, Ali AA, Ali AMA, Eissa EM, Hassan RM, Abo El-Ela FI, et al. Potential use of tailored citicoline chitosan-coated liposomes for effective wound healing in diabetic rat model. *Int J Nanomedicine.* 2022;17:555–75. [DOI](#) • [PubMed](#) • [Google Scholar](#)
23. Ordeghan AN, Khayatan D, Saki MR, Alam M, Abbasi K, Shirvani H, et al. The wound healing effect of nanoclay, collagen, and tadalafil in diabetic rats: an in vivo study. *Adv Mater Sci Eng.* 2022;2022(1):9222003. [DOI](#) • [Google Scholar](#)
24. Wang F, Liu B, Yu Z, Wang T, Song Y, Zhuang R, et al. Effects of CD100 promote wound healing in diabetic mice. *J Mol Histol.* 2018;49(3):277–87. [DOI](#) • [PubMed](#) • [Google Scholar](#)
25. Xu P, Wu Y, Zhou L, Yang X, Zhang X, Hu X, et al. Platelet-rich plasma accelerates skin wound healing by promoting re-epithelialization. *Burns Trauma.* 2020;8:tkaa028. [DOI](#) • [PubMed](#) • [Google Scholar](#)
26. Jiang P, Li Q, Luo Y, Luo F, Che Q, Lu Z, et al. Current status and progress in research on dressing management for diabetic foot ulcer. *Front Endocrinol (Lausanne).* 2023;14:1221705. [DOI](#) • [PubMed](#) • [Google Scholar](#)
27. Deng H, Li B, Shen Q, Zhang C, Kuang L, Chen R, et al. Mechanisms of diabetic foot ulceration: a review. *J Diabetes.* 2023;15(4):299–312. [DOI](#) • [PubMed](#) • [Google Scholar](#)
28. Hegazi S, Aly R, Mesilhy R, Aljohary H. Diabetic foot ulcer wound healing and tissue regeneration: signaling pathways and mechanisms. In: *Diabetic Foot Ulcers: Pathogenesis, Innovative Treatments and AI Applications.* London: IntechOpen; 2024. [DOI](#) • [Google Scholar](#)
29. Sheir MM, Nasra MMA, Abdallah OY. Phenytoin-loaded bioactive nanoparticles for the treatment of diabetic pressure ulcers: formulation and in vitro/in vivo evaluation. *Drug Deliv Transl Res.* 2022;12(12):2936–49. [DOI](#) • [PubMed](#) • [Google Scholar](#)
30. Spampinato SF, Caruso GI, De Pasquale R, Sortino MA, Merlo S. The treatment of impaired wound healing in diabetes: looking among old drugs. *Pharmaceuticals.* 2020;13(4):60. [DOI](#) • [PubMed](#) • [Google Scholar](#)
31. Shakeri F, Tebyanian H, Karami A, Babavalian H, Tahmasbi MH. Effect of topical phenytoin on wound healing. *Trauma Mon.* 2017;22(5):5. [Google Scholar](#)
32. Soltanbeigi S, Fahimi Z, Maleki M, Mozafari A, Kaffashian MR. The efficacy of *Hypericum helianthemoides* extraction with phenytoin in diabetic and non-diabetic wound healing: an experimental study in rats. *Physiol Pharmacol.* 2024;28(4):389–99. [DOI](#) • [Google Scholar](#)
33. Qadirifard M, Qadirifard MS, Tavakoli G, Mojeni FA, Mohagheghi SZ, Rafiei SK, et al. Topical phenytoin for wound healing: a narrative review. *Wound Pract Res.* 2024;32(2):66–78. [DOI](#) • [Google Scholar](#)
34. Kumar CS, Vasudeva N, Rao DV, Naidu CRA. Outcomes of topical phenytoin in the management of traumatic wounds. *J Clin Orthop Trauma.* 2021;13:116–21. [DOI](#) • [PubMed](#) • [Google Scholar](#)
35. Şimşek G, Ciftci O, Karadag N, Karatas E, Kizilay A. Effects of topical phenytoin on nasal wound healing after mechanical trauma: an experimental study. *Laryngoscope.* 2014;124(12):E449–54. [DOI](#) • [PubMed](#) • [Google Scholar](#)
36. Sayar H, Gergerlioglu N, Seringec N, Ozturk P, Bulbuloglu E, Karabay G. Comparison of efficacy of topical phenytoin with hypericin in second-degree burn wound healing: an experimental study in rats. *Med Sci Monit Basic Res.* 2014;20:36. [DOI](#) • [PubMed](#) • [Google Scholar](#)
37. Chen L, Wu D, Zhou L, Ye Y. Platelet-rich plasma promotes diabetic ulcer repair through inhibition of ferroptosis. *Ann Transl Med.* 2022;10(20):1121. [DOI](#) • [PubMed](#) • [Google Scholar](#)
38. Ni X, Shan X, Xu L, Yu W, Zhang M, Lei C, et al. Adipose-derived stem cells combined with platelet-rich plasma enhance wound healing in a rat model of full-thickness skin defects. *Stem Cell Res Ther.* 2021;12(1):226. [DOI](#) • [PubMed](#) • [Google Scholar](#)
39. Vaidyanathan L. Growth factors in wound healing: a review. *Biomed Pharmacol J.* 2021;14(3):1469–80. [DOI](#) • [Google Scholar](#)
40. Smith J, Rai V. Platelet-rich plasma in diabetic foot ulcer healing: contemplating the facts. *Int J Mol Sci.* 2024;25(23):12864. [DOI](#) • [PubMed](#) • [Google Scholar](#)
41. Guo SC, Tao SC, Yin WJ, Qi X, Yuan T, Zhang CQ. Exosomes derived from platelet-rich plasma promote the re-epithelization of chronic cutaneous wounds via activation of YAP in a diabetic rat model. *Theranostics.* 2017;7(1):81–96. [DOI](#) • [PubMed](#) • [Google Scholar](#)
42. Shi R, Lian W, Han S, Cao C, Jin Y, Yuan Y, et al. Nanosphere-mediated co-delivery of VEGF-A and PDGF-B genes for accelerating diabetic foot ulcers healing in rats. *Gene Ther.* 2018;25(6):425–38. [DOI](#) • [PubMed](#) • [Google Scholar](#)

“ To cite this article...

Al-Thubhani KT, Ibrahim DA, Al-Hammadi M. Comparative assessment of topical platelet-rich plasma and phenytoin for diabetic foot ulcer healing in a rat model. *UST J Med Sci.* 2024;4:8. <https://doi.org/10.59222/ustjms.4.8>.

📖 To publish in this journal...

Please submit your manuscript via the online submission system available at: <https://journals.ust.edu.ye/USTJMS/about/submissions>.

