



Outcomes of Conservative Management of Postoperative Adhesive Small Bowel Obstruction among Yemeni Patients

Waleed M. Gailan^{1,2}, Yasser Abdurabo Obadiel^{1,3}, Awadh Badhroos^{3*}, Khaled Alsharafy^{1,2}

¹Department of Surgery, Faculty of Medicine and Health Sciences, Sana'a University, Sana'a, Yemen

²Department of General Surgery, Kuwait University Hospital, Sana'a University, Sana'a, Yemen

³Department of General Surgery, Al-Thawra Modern General Hospital, Sana'a, Yemen

*Corresponding author: Email: awadh1983badhroos@gmail.com

ABSTRACT

Background: Adhesive small bowel obstruction (ASBO) is a surgical emergency and represents the leading cause of small bowel obstruction, accounting for 60–75% of cases. Conservative management is the main approach for treating ASBO in the absence of complications. Therefore, the present study aimed to assess the success rate, outcomes and complications of conservative management for ASBO in Yemen.

Methods: A prospective, case-series study of 102 patients with ASBO was conducted at two tertiary care hospitals in Sana'a city, Yemen; namely, Al-Thawra Modern General Hospital and Kuwait University Hospital, in the period from January 2021 to January 2023. A structured data collection sheet was used to collect pre- and postoperative data, including demographic characteristics, history of previous surgery, type of surgery, time of presentation from initial symptoms, presenting symptoms, details of non-surgical management, success or failure of conservative treatment, intraoperative findings, complications during hospital stay, and condition at discharge. Data were then analyzed and presented using descriptive statistics.

Results: Of 102 patients with ASBO, 69 patients (67.6%) responded well to conservative management and did not require surgical management, while conservative management failed and surgical intervention was



indicated for 33 patients (32.4%). The condition of most patients undergoing conservative management (88.4%) improved within 1–2 days, while five patients (7.3%) improved within one day and three patients (4.3%) improved after three days. For patients who required surgical intervention, continuous abdominal compromise was observed in 31 patients (93.9%), fever in 23 patients (69.7%), tachycardia in 28 patients (84.8%), tenderness in 31 patients (93.9%), and leukocytosis in 13 patients (39.4%). However, one patient was diagnosed with peritonitis, and one patient did not show any improvement within three days. During the surgical intervention for the 33 patients who failed conservative management, fibrous bands were identified in 51.5% of patients, while diffuse adhesions were observed in 45.4% of patients. On the other hand, 3.1% of patients showed gangrenous bowels. Out of patients undergoing surgical intervention, two patients (6%) experienced venous thromboembolism, three patients (9%) developed wound infections, two patients (6%) developed fistulas, one patient (3%) experienced a pulmonary complication, and one patient (3%) died.

Conclusion: Conservative management of Yemeni patients with ASBO is safe and preferred over surgical intervention. This approach can be attempted for 72 hours unless signs or symptoms of bowel compromise or peritonitis develop. By opting for conservative management, the risk of surgical intervention can be reduced, and the length of hospital stay can be shortened. Therefore, conservative management should be considered the primary treatment option for ASBO. However, it is crucial to carefully evaluate and monitor patients to exclude any signs of bowel compromise or peritonitis that would require discontinuation of conservative management and prompt initiation of surgical intervention.

Keywords: Adhesive small bowel obstruction ■ Conservative management ■ Surgical management ■ Outcome ■ Yemen

1. Introduction

Intestinal obstruction is one of the most common abdominal emergencies, with a complex pathophysiology and different prognostic outcomes, including death.⁽¹⁾ Postoperative adhesions are the primary causes of adhesive small bowel obstruction (ASBO), which accounts for 60–75% of small bowel obstructions.⁽²⁾ ASBO affects nearly 1 in 20 patients following abdominal or pelvic surgery, imposing a significant burden on the healthcare system.^(3–5) The mortality rate associated with ASBO ranges from 2% to 8%, presenting a clinical challenge for surgeons.⁽²⁾ Delayed diagnosis and surgical treatment of strangulating obstructions contribute to treatment

failures in ASBO cases.⁽⁶⁾ Differentiating between strangulating obstructions and simple ASBO is crucial for determining the need for immediate surgery.⁽⁶⁾

Following successful management, whether operative or non-operative, patients are at risk of developing recurrent obstruction,^(3,7–9) with many patients experiencing recurrence following conservative or surgical treatment.^(10–12) Conservative treatment may result in adhesions that increase the risk of recurrent obstruction.⁽¹¹⁾ Surgical intervention can also lead to the formation of new adhesions, potentially contributing to recurrence.⁽¹¹⁾ Therefore, the choice of treatment method (operative or conservative) may determine the risk of recur-



rence.^(11,13–15) Previous studies have compared the outcomes and complications of immediate surgery versus non-operative management of ASBO.^(16–21) Early surgical intervention within the first 48 hours of admission during the initial episode of ASBO is highly effective in reducing recurrence rates.⁽¹²⁾

To address the existing research gap regarding ASBO and its management in Yemeni patients, this study aimed to assess the success rate, outcomes and complications of conservative management for ASBO in Yemen. Furthermore, the study sought to identify the indications that warrant termination of conservative management and the intraoperative findings associated with failed conservative management of ASBO.

2. Methods

2.1. Study design, population and setting

This prospective, case-series study was conducted at two tertiary care hospitals in Sana'a city, Yemen; namely, Al-Thawra Modern General Hospital and Kuwait University Hospital, in the period from January 2021 to January 2023. The study included a total of 102 patients admitted to both hospitals with complaints of ASBO. Patients aged 18 years and older who were admitted for conservative management of post-operative ASBO were included in the present study. Patients with non-adhesive small bowel obstructions (e.g., hernia and tumor) and patients with ASBO who underwent immediate surgical intervention upon admission were excluded from the study.

2.2. Data collection

Pre- and postoperative patient data were collected through interviews and medical records using a structured data collection sheet. Variables of interest included demographic characteristics, history of previous surgery, type of surgery, time of presentation from initial symptoms, presenting

symptoms, success or failure of conservative treatment, intraoperative findings, and complications during hospital stay.

2.3. Data analysis

Data were analyzed using IBM SPSS Statistics, Version 26 (IBM Corp., Armonk, NY, USA). Descriptive statistics were used to summarize the collected data. Normally distributed continuous variables were presented as the mean and standard deviation (SD).

3. Results

3.1. Characteristics of ASBO patients undergoing conservative management

Table (1) shows that most patients presenting with ASBO at the two hospitals were females (58.8%). The mean age of patients was 35.4 ± 11.1 years, with most patients aged 18–30 years (47.1%), followed by those aged more than 40 years (31.4%). All patients presented with abdominal pain, distention, and vomiting. Absolute constipation was reported by 88.2% of patients, and the majority of patients (92.1%) experienced symptoms for 1–3 days, while six patients (5.9%) reported symptoms within the same day and two patients (2%) had symptoms lasting for more than 3 days. Regarding the last time of passage of flatus, 71.6% of patients reported passing flatus within 1–2 days, while 18 patients (17.6%) had passed flatus within less than one day, and 11 patients (10.8%) had not passed flatus for more than two days.

Among the patients included in the study, 88 individuals (86.3%) reported no previous history of a similar problem related to ASBO. However, 14 patients (13.7%) had a prior history of a similar problem (Table 1). Of these patients, eight patients (7.8%) had previously undergone operative interventions for ASBO, and six patients (5.9%) had a



history of conservative management for ASBO (data not shown).

The majority of patients (33.3%) had previous appendectomies, followed by those with gynecological and colorectal surgeries (28.4% and 17.3%, respectively). However, other types of surgeries, including abdominal gunshot injuries, perforated peptic ulcers, hernias and cholecystectomy, accounted for 24.5% of the cases (Table 1).

Table 1: Sociodemographic and clinical characteristics of ASBO patients undergoing conservative management at Al-Thawra Modern General Hospital and Kuwait University Hospital in Sana'a city, Yemen (Jan. 2021–Jan. 2023)*

Characteristics	n (%)
Gender	
Male	42 (41.2)
Female	60 (58.8)
Age (years)	
18–30	48 (47.1)
31–40	22 (21.5)
>40	32 (31.4)
Mean (SD): 35.4 ± 11.1	
Clinical symptoms	
Abdominal pain	102 (100.0)
Abdominal distension	102 (100.0)
Vomiting	102 (100.0)
Duration of symptoms at admission (days)	
<1	6 (5.9)
1–3	94 (92.1)
>3	2 (2.0)
Type of constipation	
Absolute	90 (88.2)
Relative	12 (11.8)
Last time of flatus passage (days)	
<1	18 (17.6)
1–2	73 (71.6)
>2	11 (10.8)
History of previous surgeries	
Appendectomy	33 (33.3)
Gynecological surgery	27 (28.4)
Colorectal surgery	17 (17.3)
Other ^a	25 (24.5)
History of similar attacks	
Yes	14 (13.7)
No	88 (86.3)

* The total number of patients was 102. ^a These included abdominal gunshot injuries, perforated peptic ulcers, hernias and cholecystectomy. ASBO, adhesive small bowel obstruction; SD, standard deviation.

3.2. Conservative management outcomes

Of 102 patients with ASBO, 69 patients (67.6%) responded well to conservative treatment and did not require surgical management, while conservative treatment failed and surgical intervention was indicated for 33 patients (32.4%). The condition of most patients undergoing conservative management (88.4%) improved within 1–2 days, while five patients (7.3%) improved within one day and three patients (4.3%) improved after three days. For patients who required surgical intervention, continuous abdominal pain was observed in 31 patients (93.9%), fever in 23 patients (69.7%), tachycardia in 28 patients (84.8%), tenderness in 31 patients (93.9%), and leukocytosis in 13 patients (39.4%). However, one patient was diagnosed with peritonitis, and one patient did not show any improvement within three days (data not shown).

3.3. Intraoperative findings and postoperative outcomes in patients undergoing surgery

During the surgical intervention for the 33 patients with failed conservative management, fibrous bands were identified in 51.5% of patients, while diffuse adhesions were observed in 45.4% of patients. On the other hand, 3.1% of patients showed gangrenous bowels (Figure 1).

Out of patients undergoing surgical intervention, two patients (6%) experienced venous thromboembolism (VTE), three patients (9%) developed wound infections, two patients (6%) developed fistulas, one patient (3%) experienced a pulmonary complication, and one patient (3%) died (data not shown).



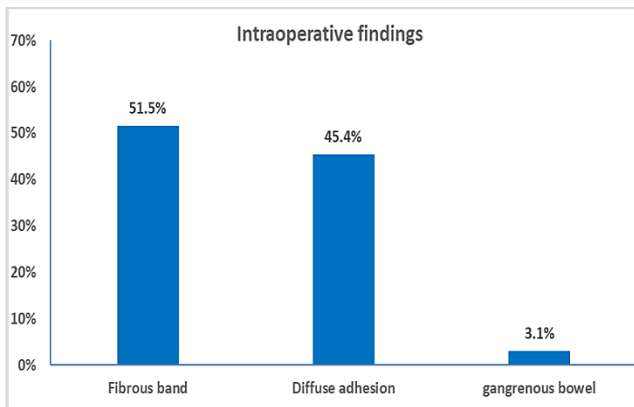


Figure 1: Intraoperative findings in ASBO patients with failed conservative management

4. Discussion

Conservative management is considered an ideal modality for ASBO in the absence of strangulation and ischemia because it is associated with fewer postoperative complications and a shorter hospital stay.⁽¹³⁾ However, many patients with ASBO experience a recurrence after conservative management. The choice of treatment methods (conservative or operative) may influence the risk of recurrence.⁽¹²⁾ In this case-series study, all patients presented with abdominal pain, distention and vomiting, with 88.2% experiencing absolute. In contrast, the majority of Colombian patients with intestinal obstruction experienced no deposition (73.2%), as well as emesis and abdominal distension (67.9%).⁽²²⁾

The majority of patients in the present study (92.1%) were admitted within 1–3 days of the onset of symptoms. Regarding the last time flatus passed, 71.6% of patients had it within 1 or 2 days, while 17.6% and 10.8% had it within less than one day and more than two days, respectively. In Nepal, 86% of patients presented within 24 hours of experiencing initial symptoms.⁽²³⁾ On the other hand, 67.9% of patients in Colombia visited emergency departments more than 24 hours after the onset of

symptoms.⁽²²⁾ These variations in seeking medical care among patients with ASBO can be attributed to differences in their educational backgrounds.

In terms of the time elapsed since the index operations, about half of the patients in the present study had undergone previous surgeries within six months. In contrast, the time span between previous surgery and presentation among Colombian patients with ASBO was 1–5 years in 30.4% of patients, spanning from one week to over 10 years.⁽²²⁾ In Nepal, the majority of patients with ASBO (76.7%) had undergone previous surgeries within a period exceeding two years.⁽²³⁾ These differences can be attributed to several factors, including the etiology of initial symptoms, the specific type of previous surgery, or the expertise of the surgeon involved.

In the present study, the highest occurrence of ASBO was observed in patients who had undergone appendectomy (33.3%), followed by those undergoing gynecological surgeries (28.4%). In contrast, most patients with ASBO in Nepal and Colombia had undergone pelvic and gynecological surgeries, followed by those undergoing appendectomy.^(22, 23) In Spain, on the other hand, most patients with ASBO had undergone appendectomy, followed by those undergoing colonic and gynecological surgeries.⁽²⁴⁾

In the present study, the majority of patients (86.3%) had not experienced a similar problem in the past, while 13.7% of them had a previous history of a similar problem that was managed surgically or conservatively. In comparison, 37.5% of patients in Nepal had a history of similar attacks and were managed conservatively.⁽²³⁾

All patients in the present study underwent decompression and received intravenous (IV) fluids, electrolyte correction and antibiotics, with conservative management being successful in approximately two-thirds of the patients and surgical

intervention being required for the remaining third. The success rate of conservative management among patients in this study was higher than that (53.8%) reported for Russian patients with ASBO.⁽²⁵⁾ However, a higher success rate of conservative management was observed among Colombian and Spanish patients with ASBO, with rates of 80.4% and 85.6%, respectively.^(22,24)

Patients who underwent conservative management for their symptoms in the present study took a maximum of three days to achieve resolution, with the majority of patients (88.4%) responding to conservative management improving within 1–2 days and the minority within less than one day (7.3%) and within three days (4.3%). However, in one patient, conservative management was unsuccessful after three days due to the presence of a dense fibrous band that caused the bowel to kink around it, necessitating surgical intervention. Therefore, it can be concluded that patients with ASBO predominantly respond to conservative management within the first three days.

In the present study, for patients who did not respond to conservative management, several symptoms were observed. Continuous abdominal pain was reported in 31 patients (93.9%), fever in 23 patients (69.7%), tachycardia in 28 patients (84.8%), tenderness in 31 patients (93.9%), and leukocytosis in 13 patients (39.4%). Additionally, one patient (3%) developed peritonitis, while another patient (3%) did not experience improvement within three days. In Spain, patients were considered to have complete ASBO if symptoms of strangulation developed or if the obstruction did not resolve spontaneously after 4–5 days.⁽²⁴⁾ Furthermore, if Gastrografin failed to reach the colon after 24 hours, a laparotomy was performed.⁽²⁴⁾

In the present study, during surgical management of 33 patients, fibrous bands were observed in more than one-half of patients, followed by diffuse

adhesion in 15 patients (45.4%) and gangrene in one patient (3.1%). In contrast, the majority of Colombian patients undergoing surgical management experienced adhesions (81.8%), followed by necrosis (9.1%) and perforations (9.1%).⁽²²⁾ On the other hand, adhesions and bands were the findings observed during surgical management in Nepalese patients, and all of them had good outcomes after undergoing adhesiolysis.⁽²³⁾

During the hospitalization period in the present study, six patients (18.2%) experienced complications, including VTE, wound infections, fistulas, and pulmonary complications. However, one patient died due to sepsis and multiorgan failure. In Nepalese patients, the complications observed were specifically wound infections and burst abdomen.⁽²³⁾ At the time of discharge, 95.1% of patients in the present study were alive without complications, while 3.9% of patients were alive with complications and one patient died. Likewise, 90% of Colombian patients were discharged from the hospital without complication, with the death of only one patient.⁽²²⁾

This study is limited by its small sample size and its implementation in only two tertiary care hospitals. Accordingly, its findings may not be generalizable to ASBO patients in the whole country without larger-scale studies. However, it provides insights into the outcomes of conservative management of postoperative ASBO among Yemeni patients.

5. Conclusion

Conservative management of Yemeni patients with ASBO is safe and preferred over surgical intervention. This approach can be attempted for 72 hours unless signs or symptoms of bowel compromise or peritonitis develop. By opting for conservative management, the risk of surgical intervention can be reduced, and the length of hospital stay can be



shortened. Therefore, conservative management should be considered the primary treatment option for ASBO. However, it is crucial to carefully evaluate and monitor patients to exclude any signs of bowel compromise or peritonitis that would require discontinuation of conservative management and prompt initiation of surgical intervention.

Acknowledgments

We thank the medical staff and administrative team at Al-Thawra Modern General Hospital for their invaluable support in providing us with the necessary resources and facilitating this research project of candidates for the Arab Board of Surgery. Additionally, we extend our appreciation to the Yemen Medical Council for their continued support throughout this endeavor.

Ethical approval and consent

This study was approved by the Research Ethics Committee of Al-Thawra Modern General Hospital. Before surgery, verbal consent was obtained from all patients. In addition, we adhered to the principles of the Declaration of Helsinki when conducting this study.

Conflict of Interest

The authors declare no conflict of interest associated with this article.

Funding

Not applicable.

References

1. Mu JF, Wang Q, Wang SD, Wang C, Song JX, Jiang J, et al. Clinical factors associated with intestinal strangulating obstruction and recurrence in adhesive small bowel obstruction: a retrospective study of 288 cases. *Medicine (Baltimore)*. 2018;97(34):e12011. [DOI](#) ● [PubMed](#) ● [Google Scholar](#)
2. Medvecz AJ, Dennis BM, Wang L, Lindsell CJ, Guillamondegui OD. Impact of operative management on recurrence of adhesive small bowel obstruction: a longitudinal analysis of a statewide database. *J Am Coll Surg*. 2020;230(4):544–51. [DOI](#) ● [PubMed](#) ● [Google Scholar](#)
3. Treves F. Intestinal obstruction: its varieties with their pathology, diagnosis, and treatment: Cassell; 1899.
4. Williams NS, O'Connell PR, McCaskie A. *Bailey & Love's Short Practice of Surgery*: CRC press; 2018.
5. Sanfey H, Dunnington GL. *Greenfield's Surgery: Scientific Principles and Practice*. Lippincott Williams & Wilkins; 2012.
6. Barmparas G, Branco BC, Schnuriger B, Lam L, Inaba K, Demetriades D. The incidence and risk factors of post-laparotomy adhesive small bowel obstruction. *J Gastrointest Surg*. 2010;14(10):1619–28. [DOI](#) ● [PubMed](#) ● [Google Scholar](#)
7. Welch JP. *Bowel obstruction: differential diagnosis and clinical management*. Philadelphia: Saunders;1987.
8. Wangenstein OH, Paine JR. Treatment of acute intestinal obstruction by suction with the duodenal tube. *JAMA*. 1933;101(20):1532–9. [Google Scholar](#)
9. Paine JR, Carlson HA, Wangenstein OH. The postoperative control of distention, nausea and vomiting: a clinical study with reference to the employment of narcotics, cathartics, and nasal catheter suction-siphonage. *JAMA*. 1933;100(24):1910–7. [Google Scholar](#)
10. Bauer J, Keeley B, Krieger B, Deliz J, Wallace K, Kruse D, et al. Adhesive small bowel obstruction: early operative versus observational management. *Am Surg*. 2015;81(6):614–20. [DOI](#) ● [PubMed](#) ● [Google Scholar](#)
11. O'Connell PR, McCaskie AW, Sayers RD. *Bailey & Love's Short Practice of Surgery*. 27 ed: Taylor & Francis Group; 2018.
12. Delestre M, Berge P, Aubé C, Hamy A, Hamel JF, Paisant A, et al. Nasogastric tube after small bowel obstruction surgery could be avoided: a retrospective cohort study. *Eur J Trauma Emerg Surg*. 2022;48(1):39–45. [DOI](#) ● [PubMed](#) ● [Google Scholar](#)
13. Netter FH, Hansen JT. *Netter's Clinical Anatomy*. 4th ed. Philadelphia: Elsevier; 2019.
14. Penman ID, Ralston SH, Strachan MW, Hobson R. *Davidson's Principles and Practice of Medicine E-Book*: Elsevier Health Sciences; 2022.
15. Sabiston D, Townsend C. *Sabiston Textbook of Surgery: The Biological Basis of Modern Surgery*. Amsterdam: Elsevier; 2016.
16. Milamed DR, Hedley-Whyte J. Contributions of the surgical sciences to a reduction of the mortality rate in the United States for the period 1968 to 1988. *Ann Surg*. 1994;219(1):94–102. [DOI](#) ● [PubMed](#) ● [Google Scholar](#)
17. Takeuchi K, Tsuzuki Y, Ando T, Sekihara M, Hara T, Yoshikawa M, et al. Clinical studies of strangulating small bowel obstruction. *Am Surg*. 2004;70(1):40–4. [DOI](#) ● [PubMed](#) ● [Google Scholar](#)
18. Dayton MT, Dempsey DT, Larson GM, Posner AR. New paradigms in the treatment of small bowel obstruction. *Curr Probl Surg*. 2012;49(11):642–717. [DOI](#) ● [PubMed](#) ● [Google Scholar](#)
19. Scott FI, Osterman MT, Mahmoud NN, Lewis JD. Secular trends in small-bowel obstruction and adhesiolysis in the United States: 1988–2007. *Am J Surg*. 2012;204(3):315–20. [DOI](#) ● [PubMed](#) ● [Google Scholar](#)
20. Scott JW, Olufajo OA, Brat GA, Rose JA, Zogg CK, Haider AH, et al. Use of national burden to define operative emergency general surgery. *JAMA Surg*. 2016;151(6):e160480. [DOI](#) ● [PubMed](#) ● [Google Scholar](#)



21. Vincenzo N. Management of intestinal obstruction. In: Dmitry Victorovich G, editor. Actual Problems of Emergency Abdominal Surgery. Rijeka: IntechOpen; 2016. [DOI](#) ● [Google Scholar](#)
22. Idrobo AA, Bastidas BE, Yasno LM, Vargas AL, Merchán-Galvis AM. Presentation and outcome of conservative management of intestinal obstruction caused by adhesions in Cauca. Rev Colomb Gastroenterol. 2020;35:447–54. [DOI](#) ● [Google Scholar](#)
23. Niyaf A, Bhandari R, Singh K. Management of adhesive intestinal obstruction. J Inst Med Nepal. 2010;32(2). [Google Scholar](#)
24. Biondo S, Parés D, Mora L, Martí Ragué J, Kreisler E, Jaurrieta E. Randomized clinical study of Gastrografin administration in patients with adhesive small bowel obstruction. Br J Surg. 2003;90(5):542–6. [DOI](#) ● [PubMed](#) ● [Google Scholar](#)

To cite this article...

Gailan WM, Obadiel YA, Badhroos A, Alsharafy K. Outcomes of Conservative Management of Postoperative Adhesive Small Bowel Obstruction among Yemeni Patients. UST J Med Sci. 2024;2:3. <https://doi.org/10.59222/ustjms.2.2.A2>

To publish in this journal...

Please submit your manuscript via the online submission system available at: <https://journals.ust.edu.ye/USTJMS/about/submissions>.

